



PATIENT

Bailey Tedrow

SPECIES

Canine

BREED

Boxer Mix

SEX

FS

AGE

12 y

WEIGHT

48.8 lb

INTERPRETED BY

Keith Blass, DVM, MS,
DACVIM (Cardiology)

IMAGING PERFORMED BY

Trish Turner, CVT

HOSPITAL NAME

Straley Vet. Associates

REFERRING VET

Jenny Wenrich, DV

INVOICE

DATE

12/16/25

PRESENTING CLINICAL SIGNS

Grade 2-3/6 murmur. Cough that is non-responsive to doxycycline. Decreased appetite, sometimes has less energy. Started on pimobendan 5 mg BID.

ECHOCARDIOGRAPHIC FINDINGS

2D, M-mode, and Doppler study.

There is mild left atrial dilation. The mitral valve leaflets are mildly thickened and exhibit mild systolic prolapse. There is Doppler evidence of mitral regurgitation present. There is mild left ventricular dilation. Left ventricular systolic function is hyperdynamic. The aorta and aortic valve appear normal. Right atrial and right ventricular dimensions are normal. The tricuspid valve appears normal, though trace tricuspid regurgitation is present. The pulmonary artery and pulmonic valve appear normal. No pericardial effusion or cardiac masses are seen.

LA - 50.8 mm

LVIDd - 47.4 mm

LVIDs - 22.5 mm

FS - 52.5%

RA - 30.0 mm

ASSESSMENT/RECOMMENDATIONS

Degenerative mitral valve disease

This examination demonstrates regurgitation of blood across Bailey's mitral valve resulting from degenerative valve disease. Secondary to her regurgitation, Bailey has mild dilation of both her left atrium and left ventricle, though her left ventricular systolic function is well-preserved. As only mild left atrial dilation is present, it's unlikely that mainstem bronchial compression is contributing to Bailey's cough. Bailey's risk for the development of other clinical signs secondary to her mitral valve disease, such as exercise intolerance, syncope, and labored breathing, is mildly increased, therefore, careful monitoring for these is recommended.

No reason for Bailey's decreased appetite and intermittent low energy is appreciated in this exam, though I can't rule out pimobendan as the cause.

Continued use of pimobendan is warranted based on this exam, though the medication should be stopped for a few days and restarted at half the dose if Bailey's decreased appetite and lower energy persist. As for Bailey's cough, a trial with a cough suppressant, such as hydrocodone, is recommended, if the cough persists.

A recheck echocardiogram is recommended in 6-9 months. Recheck radiographs are recommended if Bailey experiences difficulty breathing.



PATIENT

Bailey Tedrow

SPECIES

Canine

BREED

Boxer Mix

SEX

FS

AGE

12 y

WEIGHT

48.8 lb

INTERPRETED BY

Keith Blass, DVM, MS,
DACVIM (Cardiology)

IMAGING PERFORMED BY

Trish Turner, CVT

HOSPITAL NAME

Straley Vet. Associates

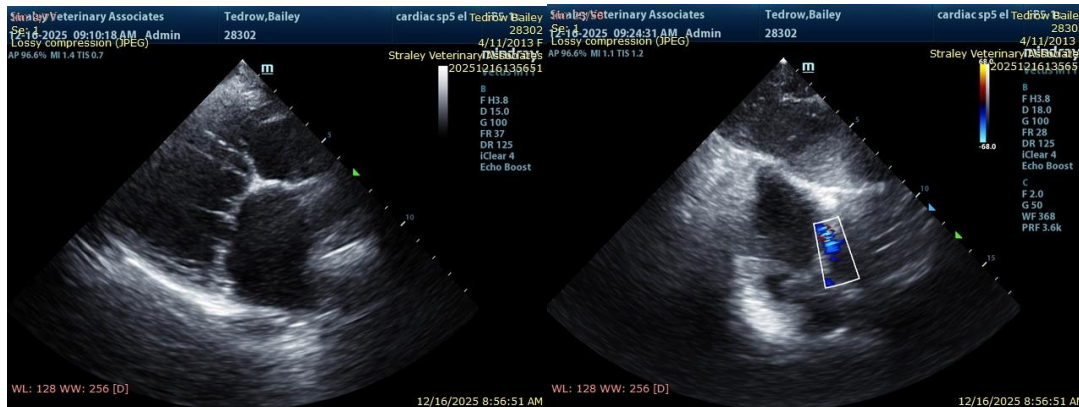
REFERRING VET

Jenny Wenrich, DV

INVOICE

DATE

12/16/25



The information and recommendations provided are based on the images presented by the referring veterinarian/sonographer. No evaluation can be communicated regarding pathology that was not visible in the image/video clips provided.

Thank you for this referral. If the clinical or image interpretation does not parallel your findings or if I can be of any further assistance please contact me.

Keith Blass, DVM, MS, DACVIM (Cardiology)

info@SonoPath.com